

## Disseminated epithelioid hemangioendothelioma of the liver - a case report and review of the literature

Andrzej Lemieszek<sup>1</sup>, Danuta Bręborowicz<sup>2</sup>, Elżbieta Wójcik<sup>1</sup>, Jerzy Załuski<sup>1</sup>

*The term „epithelioid hemangioendothelioma” was first used by Weiss and Enzinger in 1982. They presented a study of 41 soft tissue vascular tumors with unpredictable malignant potential, assessed as intermediate between benign hemangioma and malignant angiosarcoma. The key to the diagnosis is the presence of cells containing factor VIII related-antigen, which confirms its endothelial origin. Liver is the most common localization of the tumour. In the absence of metastases the treatment of choice is radical hepatic resection and even orthotopic liver transplantation may be justified as a curative procedure. Case reports only are found on the systemic chemotherapy of epithelioid hemangioendothelioma. The prognosis is significantly better than for other hepatic malignancies. We present a case of a disseminated epithelioid hemangioendothelioma of the liver. Although a short – term improvement was observed, the use of chemotherapy in this case worsened the quality of life.*

### Haemangioendothelioma epithelioides wątroby, postać uogólniona - opis przypadku i przegląd piśmiennictwa

*Termin: „Haemangioendothelioma epithelioides” został po raz pierwszy użyty przez Weiss i Enzinger'a w 1982 roku. Autorzy ci opisali grupę 41 guzów tkanek miękkich pochodzących ze śródbłonka naczyniowego, które ze względu na przebieg kliniczny zostały zakwalifikowane jako ogniwo pośrednie pomiędzy haemangioma – naczyniak krwionośny, a angiosarcoma – mięsak naczyń krwionośnych. Naturę naczyniową tego nowotworu potwierdza obecność czynnika VIII-RAg w badaniu immunohistochemicznym, co stanowi jednocześnie podstawę do postawienia rozpoznania. Najczęstszym umiejscowieniem pierwotnym tego nowotworu jest wątroba. Leczeniem z wyboru postaci wątrobowej bez przerzutów odległych jest częściowe jej usunięcie; ponadto można rozważyć zastosowanie ortotopowego przeszczepu wątroby. Doniesienia o prowadzeniu chemioterapii systemowej w tej jednostce chorobowej mają charakter kazuistyczny. Rokowanie jest znamienne lepsze w porównaniu z innymi nowotworami złośliwymi wątroby. Autorzy przedstawili przypadek 28-letniego pacjenta z postacią uogólnioną haemangioendothelioma epithelioides wątroby, u którego podjęto leczenie systemowe. Przy zastosowaniu cytostatyków: etopozyd, ifosfamid, cisplatyna uzyskano krótkotrwałą poprawę. Wydaje się, że próba leczenia wpłynęła jednak na pogorszenie jakości życia pacjenta.*

**Key words:** epithelioid haemangioendothelioma of the liver, metastatic disease, diagnosis, treatment

**Słowa kluczowe:** haemangioendothelioma epithelioides wątroby, postać uogólniona, diagnostyka, leczenie

### Introduction

Epithelioid hemangioendothelioma is a rare neoplasm. There are about 270 case reports in medical literature and the largest group of patients (137) were followed and reported in the years 1966-1997 by Makhlof et al. [1]. The name „epithelioid hemangioendothelioma” was used for the first time in 1982 by Weiss and Enzinger who reported on the group of 41 soft tissue tumours derived

from vascular endothelium and classified, based on their clinical presentation, as an intermediate entity between haemangioma and angiosarcoma [2]. In 1984 Ishak et al. were the first to present the report on 32 cases of primary liver involvement with epithelioid hemangioendothelioma [3]. This publication aroused great interest in the newly discovered type of a neoplasm.

Our case report presents this rare neoplasm in a 28-year old patient and discusses other relevant reports.

### Case report

A 28-year old patient went through initial diagnostic process in a district hospital where he had presented with

<sup>1</sup> Department of Chemotherapy

<sup>2</sup> Laboratory of Pathology

Greatpoland Center of Oncology, Poznań, Poland

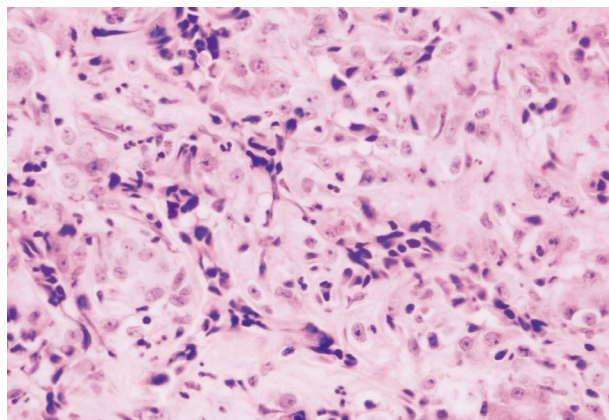


Fig. 1. Cellular neoplastic tissue composed of epithelioid cells arranged in nests and cords. Focally small intracytoplasmic vacuoles are seen (H&E, original magnification 400 X)

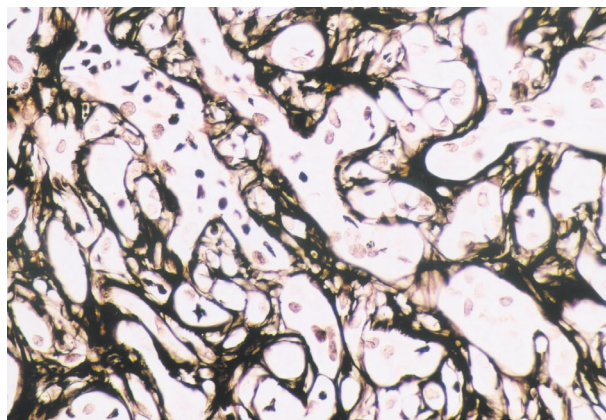


Fig. 2. Nests of epithelioid cells surrounded by reticulin fibres (reticulin acc. to Gomori, original magnification 400 X)

nonspecific symptoms including weight loss (10 kg in 2 months), fever of up to 39°C during afternoon hours, and lumbar pain of moderate intensity. Ultrasonography (USG) revealed a normoechogenic focal lesion of 29 mm diameter located in the right lobe of the liver. The CT liver scan revealed the presence of 3 round, poorly delineated, low density areas, with the largest the size of 32 x 25 mm. In November 1999 the patient was hospitalised in Wielkopolskie Centrum Onkologii in Poznań where he underwent laparotomy and had a liver biopsy performed for subsequent microscopic examination. A fragment of liver (1.7 x 1.2 x 0.6 cm) was received for examination. Almost the entire volume of this fragment was occupied by a gray-white, firm nodule surrounded by a thin rim of the liver tissue. The material was fixed in formalin and embedded in paraffin. Paraffin sections were stained with haematoxylin and eosin, Gomori's silver technique for reticulin fibres and used for immunohistochemistry. The same staining techniques were used for decalcified 2.5 cm long core biopsy from the iliac crest.

Solid neoplastic infiltration composed of epithelioid cells was observed microscopically in the liver lesion. Cytoplasm of these cells was either clear or acidophilic. In many cells incipient vascular lumina were observed (so called blister cells). Nuclei of these cells were vesicular and exhibited signs of atypia (small to intermediate degree). The cells were arranged in nests and cords surrounded by reticulin fibers. The central part of the lesion was necrotic and fibrotic while at the periphery atrophic liver trabeculae were seen between neoplastic nests. Positive reaction with antibody CAM 5.2 facilitated identification of liver trabeculae while this reaction was negative in the neoplastic cells. These cells were also negative in the reaction with antibodies against LCA, desmin, synaptophysin and cytokeratin MNF 116. The neoplastic cells were positive for factor VIII, vimentin and focally for CD34. Neoplastic infiltration with the same morphological features as those observed in the liver was also observed in the bone marrow. In both cases high cellularity was observed. The last feature according to Makhoulouf [1] is the only morphological parameter of prognostic significance.

After the diagnosis of epithelioid hemangioendothelioma had been established in December 1999 the patient was transferred to the chemotherapy ward. Physical examination revealed mild lymphadenopathy in the cervical and supraclavicular area and his general condition according to Karnofsky's scale was assessed at the level of 90%. The following laboratory results were abnormal: Hb 6.5 mmol/l; Ht 30%; sedimentation rate (SR) 127/h; LDH 608 IU/l; ALAT 49 IU/l; alkaline phosphatase 213 IU/l. Ultrasonography of the abdominal cavity revealed 3 normoechogenic foci with hypoechogenic rim, the largest of the size 49 x 39 mm with centrally located necrosis; the remaining two foci had the dimensions of 24 x 18 mm, and 13 mm in diameter, respectively. Scintigraphy revealed the presence of multifocal areas characterised by increased isotope concentration throughout the whole vertebral column. The largest lesion was located in the lumbar area, other foci were located in pelvic bones and bilaterally in the ribs. Scintigraphy results were characteristic of metastatic disease.

The first chemotherapeutic regimen with doxorubicin in the dose 75 mg/m<sup>2</sup> administered every 3 weeks was launched. Because of progression of the lesions which was confirmed through ultrasonography after the first course of treatment (new focal lesions appeared in the left lobe of the liver) as well as due to sustained fever and pain in the lumbar area the treatment with doxorubicin was discontinued and a second chemotherapeutic regimen with ifosfamide in the dose of 5 g/m<sup>2</sup> in 24-hour intravenous infusions administered every 3 weeks was initiated. After the first course of treatment with ifosfamide fever remitted and USG examination did not reveal any further dissemination or enlargement of the lesions. However, LDH rose to 1966 IU/l and SR remained high (131/h). In the subsequent course of this chemotherapeutic regimen cisplatin in the dose of 20 mg/m<sup>2</sup>/day for 5 days and etoposide in the dose of 100 mg/m<sup>2</sup>/day for 5 days were added, with the dose of ifosfamide being divided into 5 days of 1200 mg/m<sup>2</sup> (VIP protocol) to be administered every 3 weeks. This protocol of combined chemotherapy produced transient remission involving allevia-

tion of pain and fever, decrease in LDH levels (326 IU/l) and stabilisation of liver lesions. However, after the second course of this chemotherapeutic regimen (VIP) exacerbation of liver lesions (the largest focal lesion in the right lobe of size 60 x 47 mm) was revealed in ultrasonography and LDH rose to 976 IU/l. Further chemotherapy was therefore given up, with its final course having been administered in February 2000. Tolerance of the treatment was not good: the main adverse effects included anaemia (severity of 3 according to NCI scale) after the second, third and fourth course of chemotherapy, upper respiratory tract infection, with fever up to 40°C, complicated with involvement of the right vestibulo-cochlear nerve and total deafness in the right ear after the third course of chemotherapy. Further weight loss of 5 kg within 3 months and progressive malaise also ensued. Following cessation of chemotherapy the health status of the patient was assessed at 80% according to Karnofsky's scale. Due to weight loss and metastases to the bones adjunctive treatment with megestrol (Megace) 160 mg 3 x 1 tabl. and clodronic acid (Bonafos) 2 x 2 tabl. was initiated.

In May, 2000 the patient sought medical help because of intensive pain in the left hip and in lumbo-sacral segment of the spine. General health status of the patient was assessed at 60% according to Karnofsky's scale and further weight loss was observed. USG examination of the liver revealed further metastatic lesions in both lobes (the largest focal lesion of 74 x 59 mm), LDH rose to 1761 IU/l and SR was 135/h. Radiological examination of the hip bones and the lumbo-sacral spine segment confirmed the presence of metastases diagnosed initially through bone scintigraphy. Palliative irradiation of these areas brought improvement. Further symptomatic treatment was then taken over by a family physician.

## Discussion

Epithelioid hemangioendothelioma may primarily develop in the liver but also in soft tissues and in the lungs. The tumour is more frequent among women. Clinical symptoms of hepatic involvement are nonspecific – both total lack of any symptoms as well as liver failure have been reported. The initial symptoms usually reported by patients include right side epigastric pain, weight loss and weakness. Rarely, jaundice or fever may be the first symptoms. Primary liver tumour is followed by metastases in about 45% of cases and these usually involve lungs, bones, peripheral lymph nodes and, less frequently, spleen and the brain [2]. The described lesion resembles an epithelial tumour and that's why in the past it was described as an atypical form of bile duct adenocarcinoma. The vascular nature of epithelioid hemangioendothelioma is confirmed in electron microscopy by presence of Weibel-Palad bodies and by expression of VIII-Rag (factor VIII related antigen) in immunohistochemical examination. Presence of this factor confirms the diagnosis of epithelioid hemangioendothelioma and it was demonstrated in 98% of patients with this tumour. In Factor VIII negative cases demonstration of other vascular markers like CD31

or CD34 is necessary to confirm the diagnosis of epithelioid hemangioendothelioma [4].

Surgical resection is the treatment of choice for of the primary liver epithelioid hemangioendothelioma without remote metastases. In most cases, however, the liver lesions are multifocal thus rendering radical resection impossible [5]. In these cases orthotopic liver transplant should be considered, particularly in patients with severe liver dysfunction – 35 such cases have already been reported in medical literature [6]. Evaluation of different chemotherapy protocols is difficult due to the low incidence of epithelioid hemangioendothelioma and lack of prospective studies. There have been individual reports on patients treated with 5-Fluorouracil administered via the hepatic artery. The authors report alleviation of symptoms and increased survival rate of their patients [5, 7]. Sporadic attempts of hepatic artery embolisation, the method being effective in the treatment of carcinoma hepatocellulare, did not produce satisfactory results in the treatment of epithelioid hemangioendothelioma [5]. There are only sporadic case reports on the use of systemic chemotherapy. One such report presents a case of a patient with bilateral involvement of the pleura where complete remission was obtained after 6 courses of treatment with carboplatin and etoposide [8]; another case report describes a patient in whom complete remission was induced after treatment with doxorubicin [9]. A case of partial remission in a patient with disseminated disease treated with interferon 2 $\alpha$  has also been reported [10].

Epithelioid hemangioendothelioma is one of few soft tissue sarcomas poorly responding to chemotherapy – positive response ratio is less than 15%. In the case we report chemotherapy was initiated because of the age of the patient and his good general health, however both the physician and the patient were aware that chemotherapy was of merely palliative character. Based on the results of one of the reports [9] the first chemotherapeutic regimen involved administration of doxorubicin – a standard treatment for soft tissue sarcomas – this treatment being characterised by moderate degree of toxicity. Despite poor response to this therapeutic regimen, having considered good health of the patient and lack of significant deterioration of life quality, treatment with ifosfamide was initiated. Based on another case report [8] cisplatin and etoposide were added which resulted in short-term, yet spectacular improvement with remission of pain, decrease of LDH level and stable ultrasonography results for 2 months.

However, in the authors' opinion the use of systemic chemotherapy in the reported case is questionable. Administration of chemotherapeutic agents resulted in deterioration of life quality, produced loss of weight, weakness and total right ear deafness (which may have been directly caused by cisplatin).

When planning palliative systemic chemotherapy it is important to analyse the benefit to risk ratio, the risk comprising mainly the adverse effects and, consequently, deterioration of quality of patient's life. Biology of the neoplasm, its sensitivity to chemotherapy, expert opi-

nion from a pathologist, age and general health status of the patient as well as coexisting diseases should all be taken into account.

Patients with primary epithelioid hemangioendothelioma of the liver may survive for several years without any anti-cancer chemotherapy, yet they face the risk of developing liver failure which leads to death within a short period of time [2]. Prognosis in epithelioid hemangioendothelioma is, however, much more favourable than in other liver neoplasms [5].

**Andrzej Lemieszek M.D.**

Department of Chemotherapy  
Greatpoland Cancer of Oncology  
ul. Garbary 15  
61 866 Poznań, Poland  
e-mail: andrzejl@wco.pl

## References

1. Makhlof H, Ishak K, Goodman Z et al. Epithelioid hemangioendothelioma of the liver: a clinicopathologic study of 137 cases. *Cancer* 1999; 85: 562-582.
2. Weiss S, Enzinger F. Epithelioid hemangioendothelioma: a vascular tumor often mistaken for carcinoma. *Cancer* 1982; 50: 970-981.
3. Ishak K, Sesterhenn I, Goodman Z et al. Epithelioid hemangioendothelioma of the liver: a clinicopathologic and follow-up study of 32 cases. *Hum Pathol* 1984; 15: 839-852.
4. Dietze O, Davies S, Williams R et al. Malignant epithelioid hemangioendothelioma of the liver: a clinicopathological and histochemical study of 12 cases. *Histopathology* 1989; 15: 225-237.
5. Lauffer J, Zimmermann A, Krahenbuhl L et al. Epithelioid hemangioendothelioma of the liver: a rare hepatic tumor. *Cancer* 1996; 78: 2318-2327.
6. Marino I, Todo S, Tzakis A et al. Treatment of hepatic epithelioid hemangioendothelioma with liver transplantation. *Cancer* 1988; 62: 2079-2084.
7. Holley M, Cuschieri A. Epithelioid hemangioendothelioma of the liver: objective response to hepatic intra-arterial 5-Fu. *Eur J Surg Oncol* 1989; 15: 73-78.
8. Pinet C, Magnan A, Garbe L et al. Aggressive form of pleural epithelioid haemangioendothelioma: complete response after chemotherapy. *Eur Respir J* 1999; 14: 237-238.
9. Idilman R, Dokmeci A, Beyler A et al. Successful medical treatment of an epithelioid hemangioendothelioma of liver. *Oncology* 1997; 54: 171-175.
10. Roudier-Pujol C, Enjolras O, Lacrocnique J et al. Multifocal epithelioid hemangioendothelioma with partial remission after interferon alfa-2a treatment. *Ann Dermatol Venereol* 1994; 121: 898-904.

*Paper received: 14 August 2000*

*Accepted: 13 February 2001*